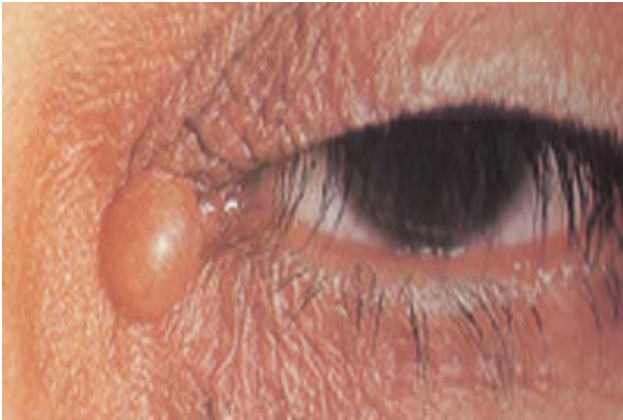


Picture Quiz

The lesion seen below has been present for many years. The patient does not complain of pain, itching or growth. This is most consistent with:



1. Apocrine hydrocystoma
2. Basal cell carcinoma
3. Chronic dacryocystitis
4. Sebaceous cell carcinoma

(See answer on page: 121)

